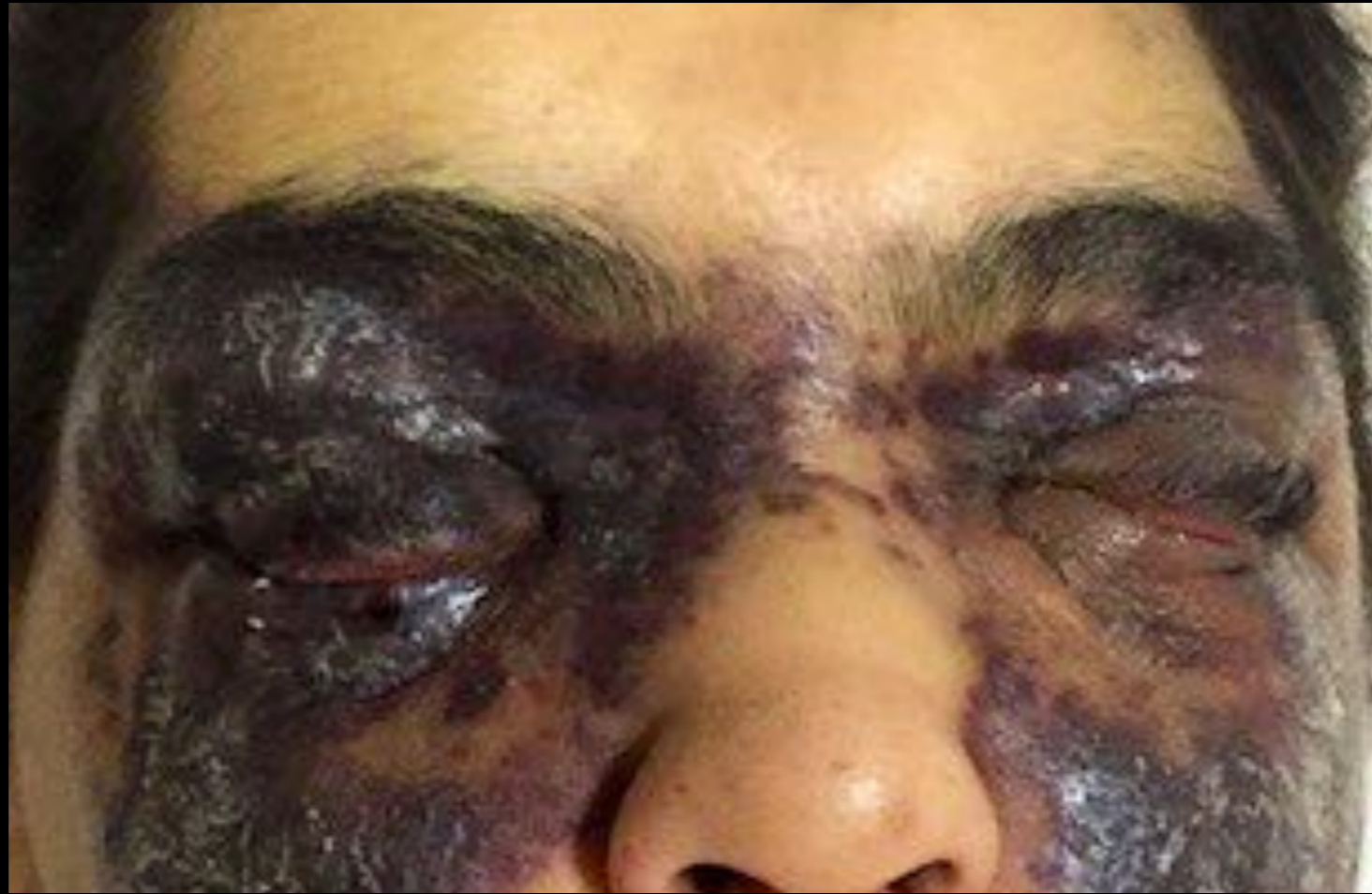

EYELID TUMOR SURPRISES

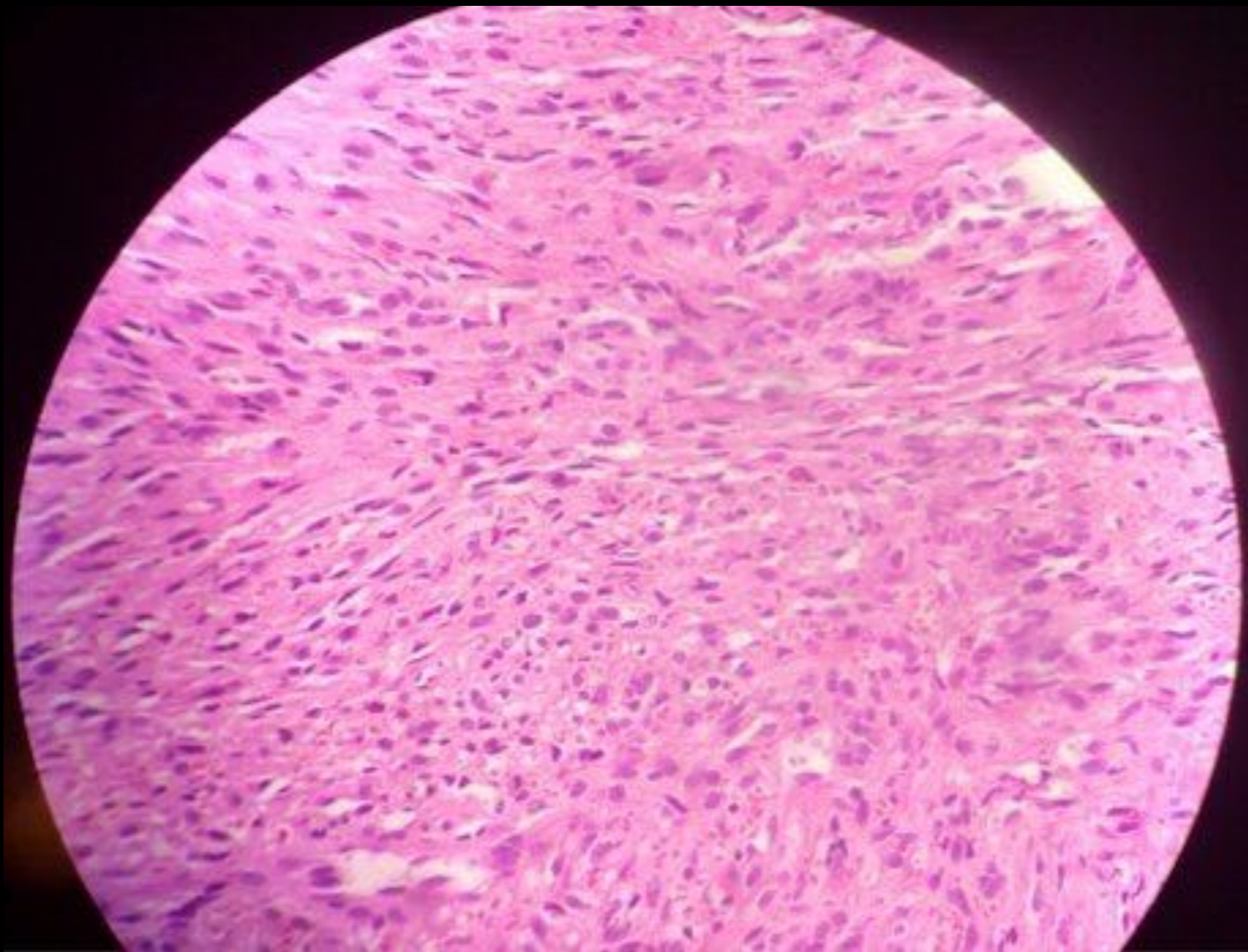
DR.VIKAS MENON,
DR.KAUSTUBH MULAY
OCULAR ONCOLOGY,& OCULAR PATHOLOGY,
CENTRE FOR SIGHT,
NEW DELHI

CASE 1

- 27yr Female
- Gradually increasing swelling on face and eyelids x 6months
- H/O Subcutaneous serum injections for cosmesis
- Antibodies to Toxoplasma, Rubella (IgG, IgM+), CMV (IgG+/IgM-)
- HIV Negative



- Nasal Swab for KOH : Negative
- Incision Biopsy from skin



IHC

- SMA: Negative
- CD 31, CD 34: Diffusely and strongly positive in spindle cells and vessels
- S 100: Negative
- Ki 67: Positive upto 25%

DIAGNOSIS

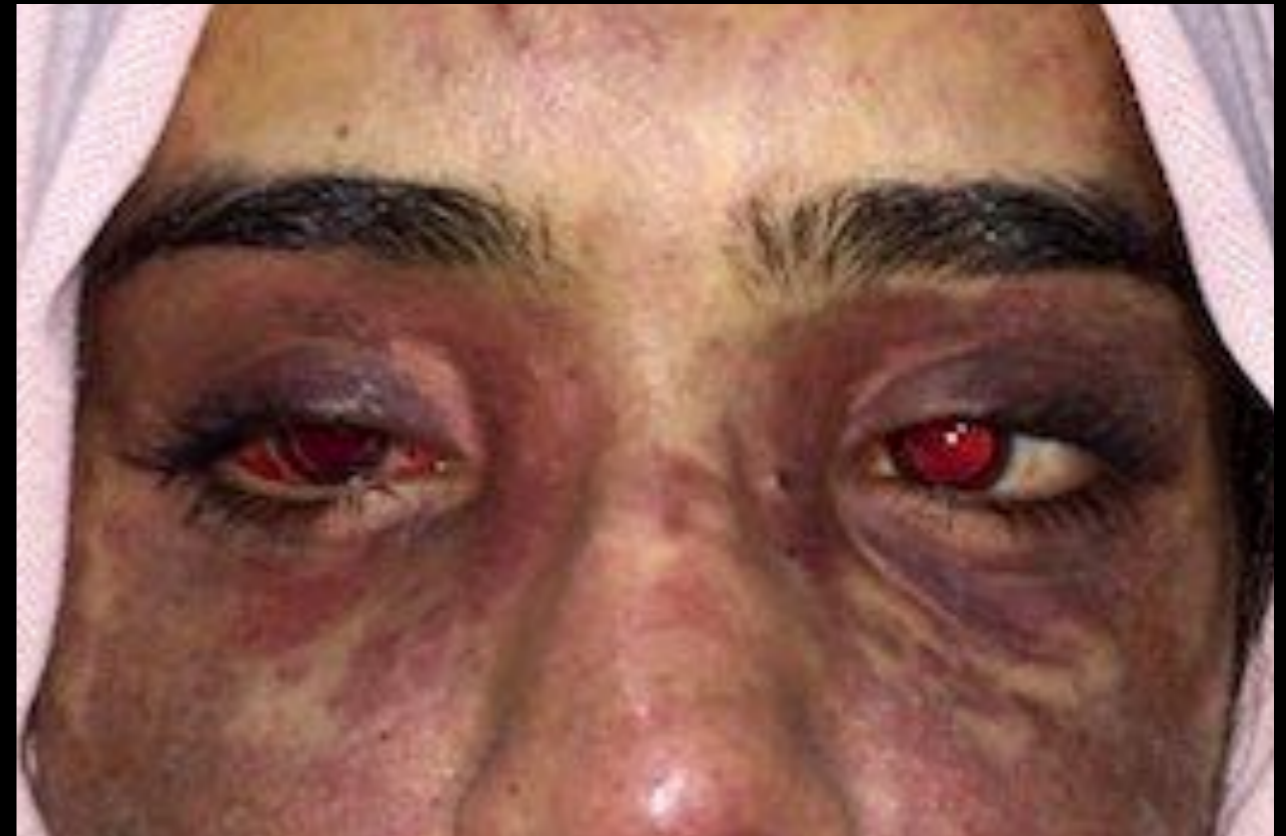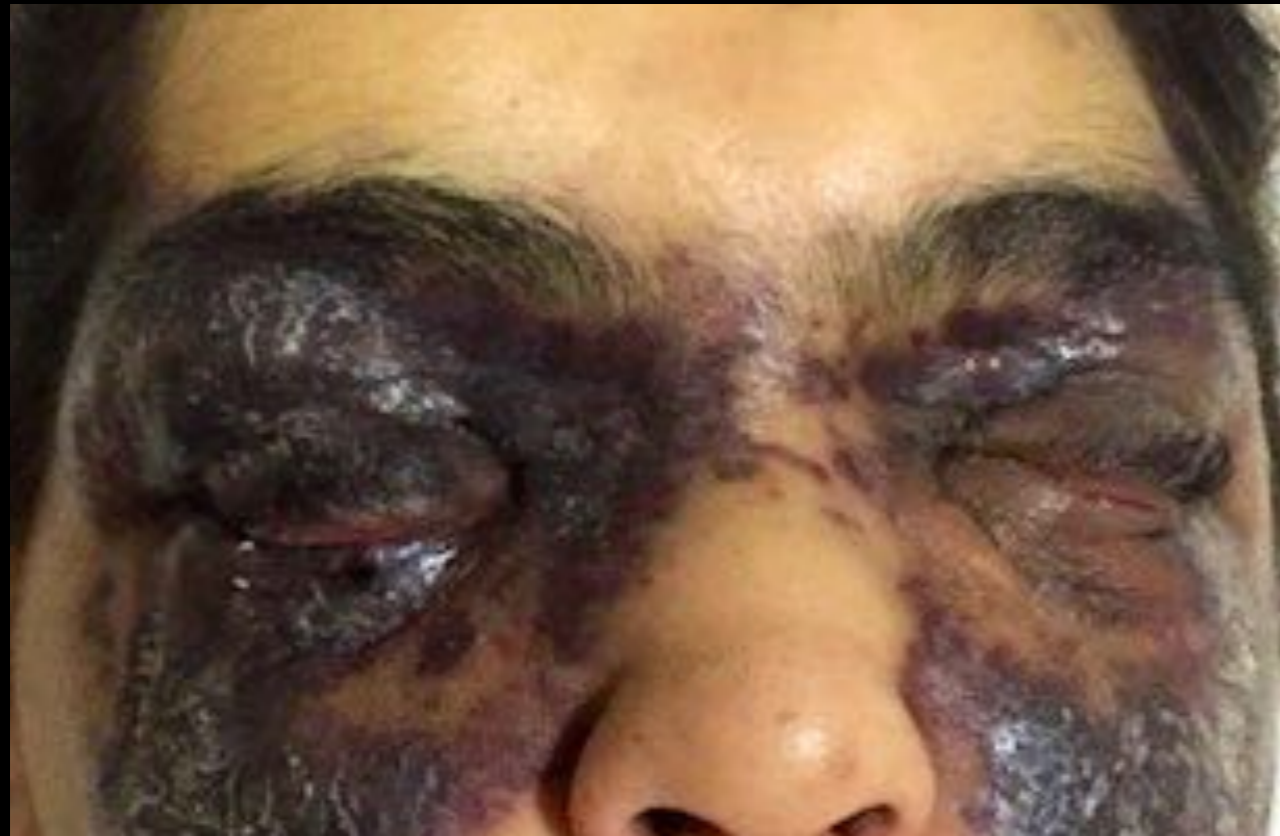- Angiosarcoma / Kaposi Sarcoma

SYSTEMIC WORK UP

- PET CT: Active lesions also seen in Lungs bilaterally, Cervical and Abdomino-pelvic nodes

TREATMENT

- Chemotherapy with Lipodox x 6 cycles

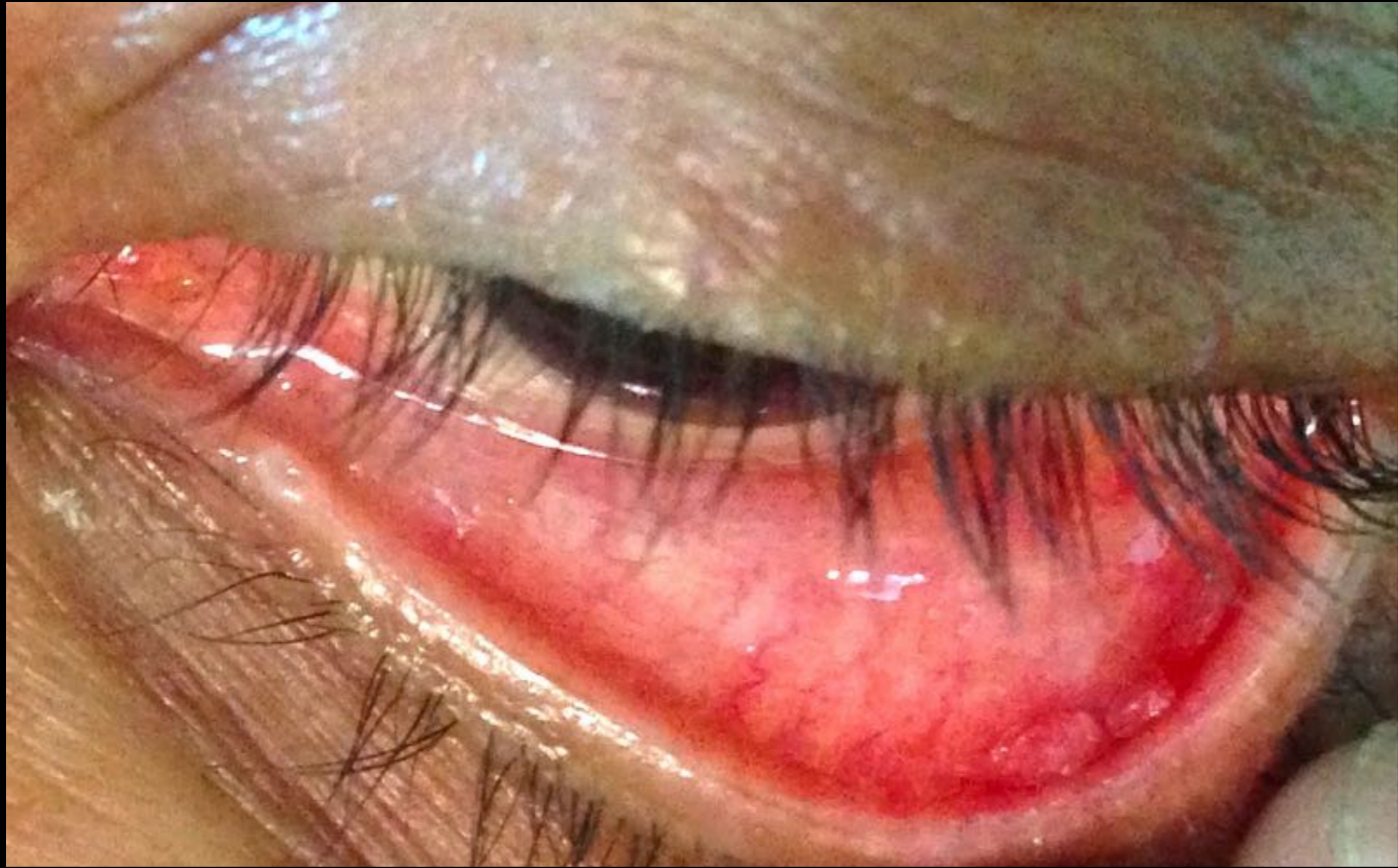

KAPOSI SARCOMA

- Classic form
- African endemic form
- Iatrogenic
- Epidemic

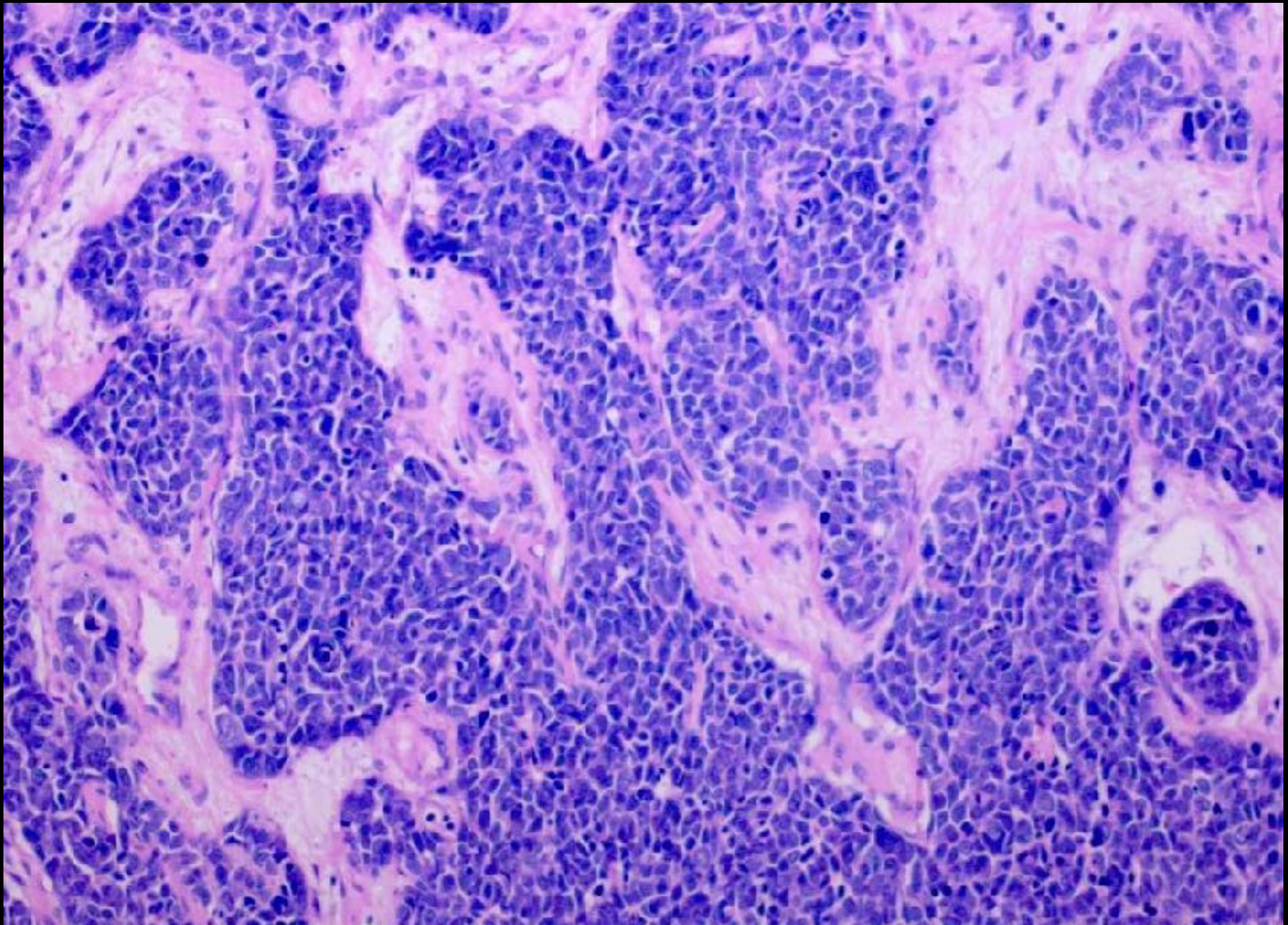
CASE 2

- 66 yr Female
- c/o Recurring nodule left lower lid
- H/O Surgery for chalazion removal same site twice earlier elsewhere
- No other systemic positive history



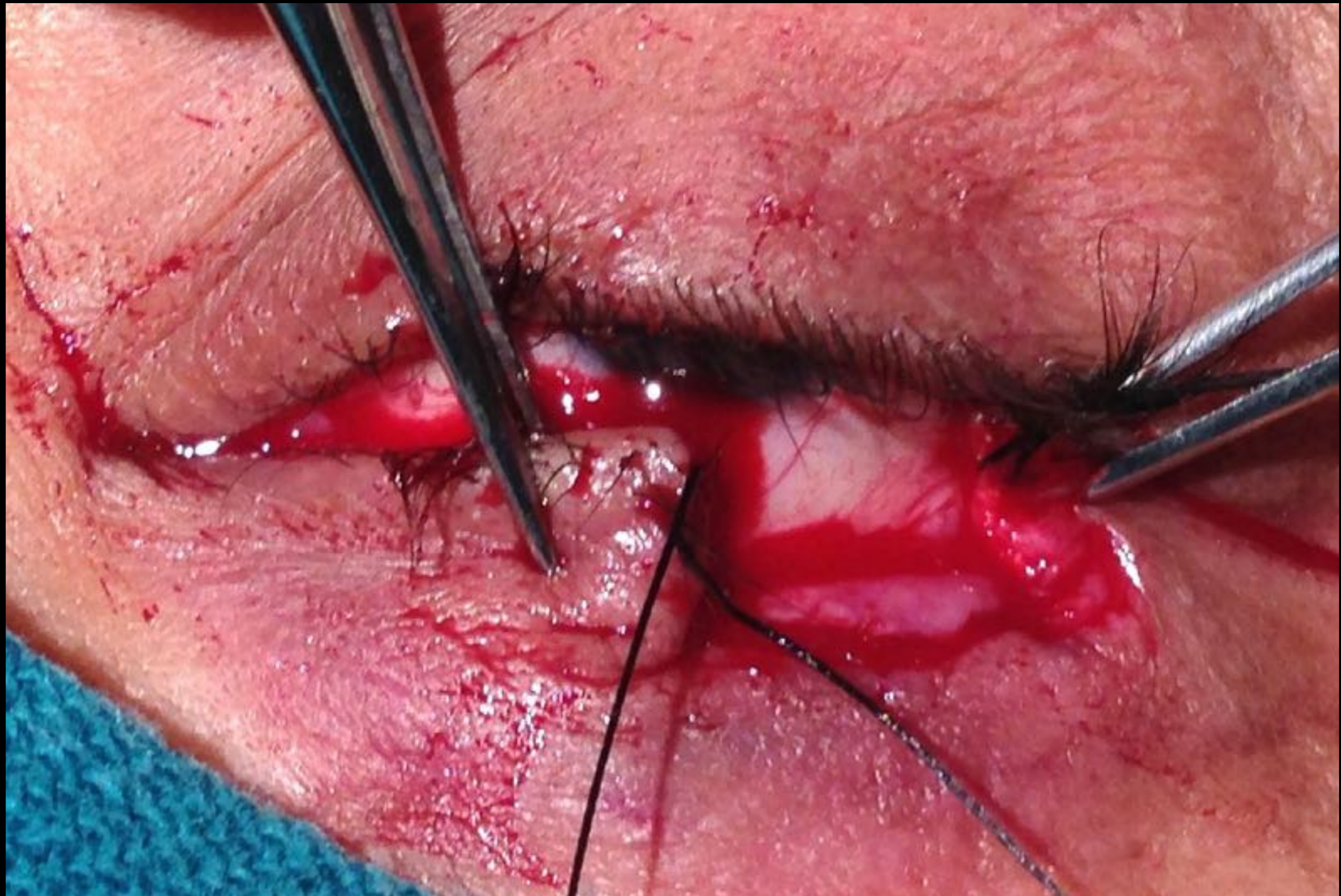
LID MARGIN, MEIBOMIAN ORIFICIES, CILIA: NORMAL

- ? Recurrent Chalazion
- ?? Sebaceous Gland Carcinoma
- Biopsy

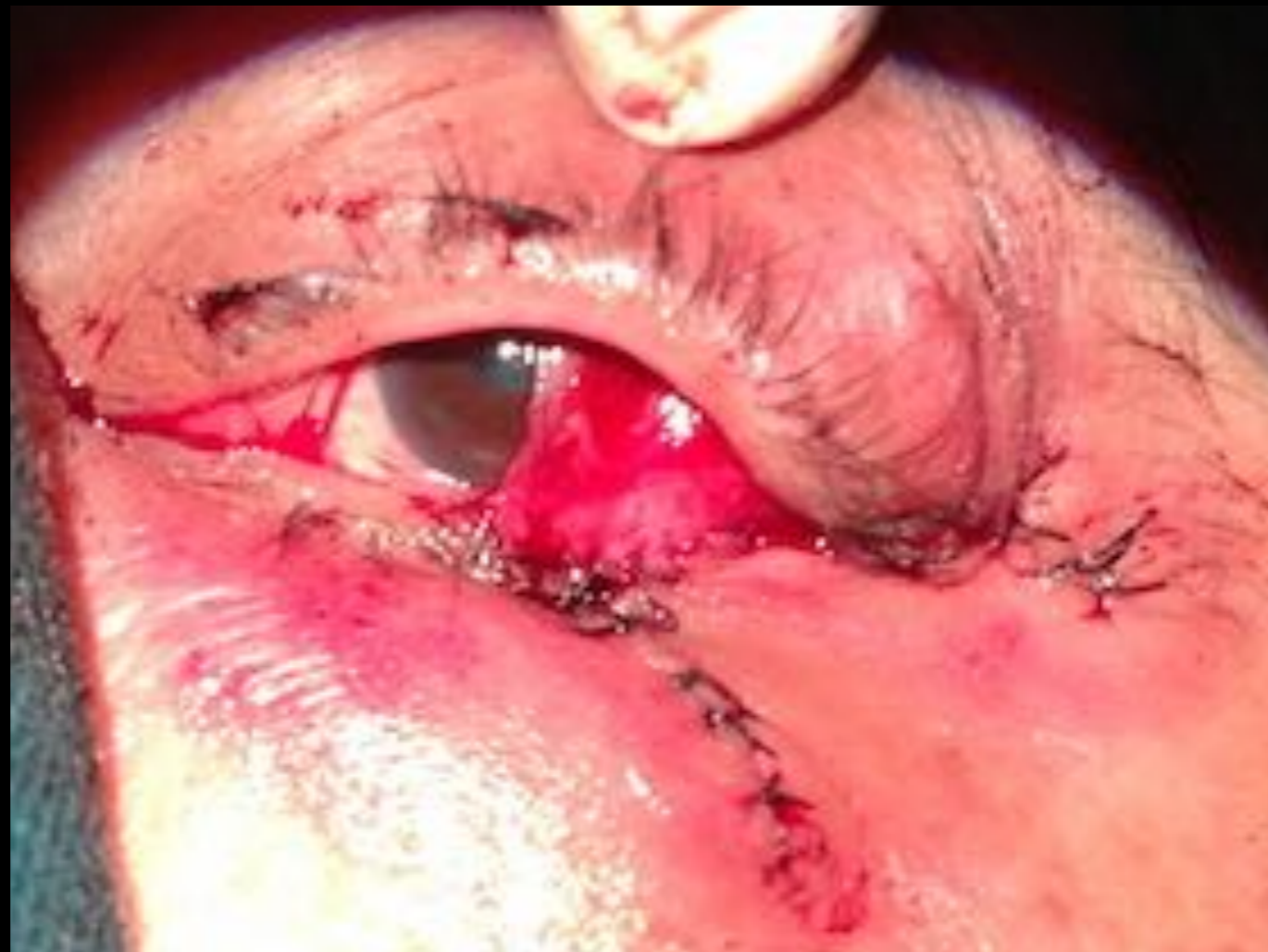

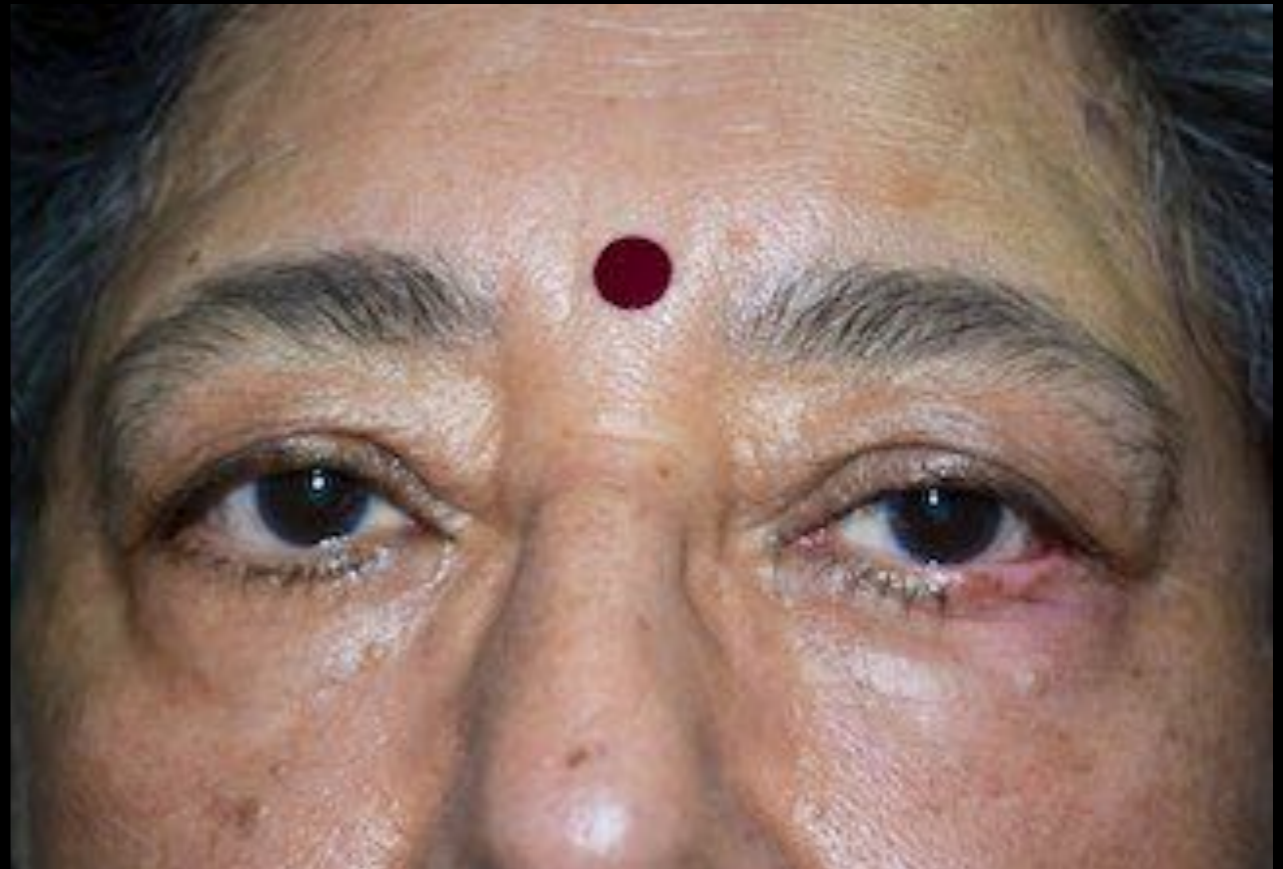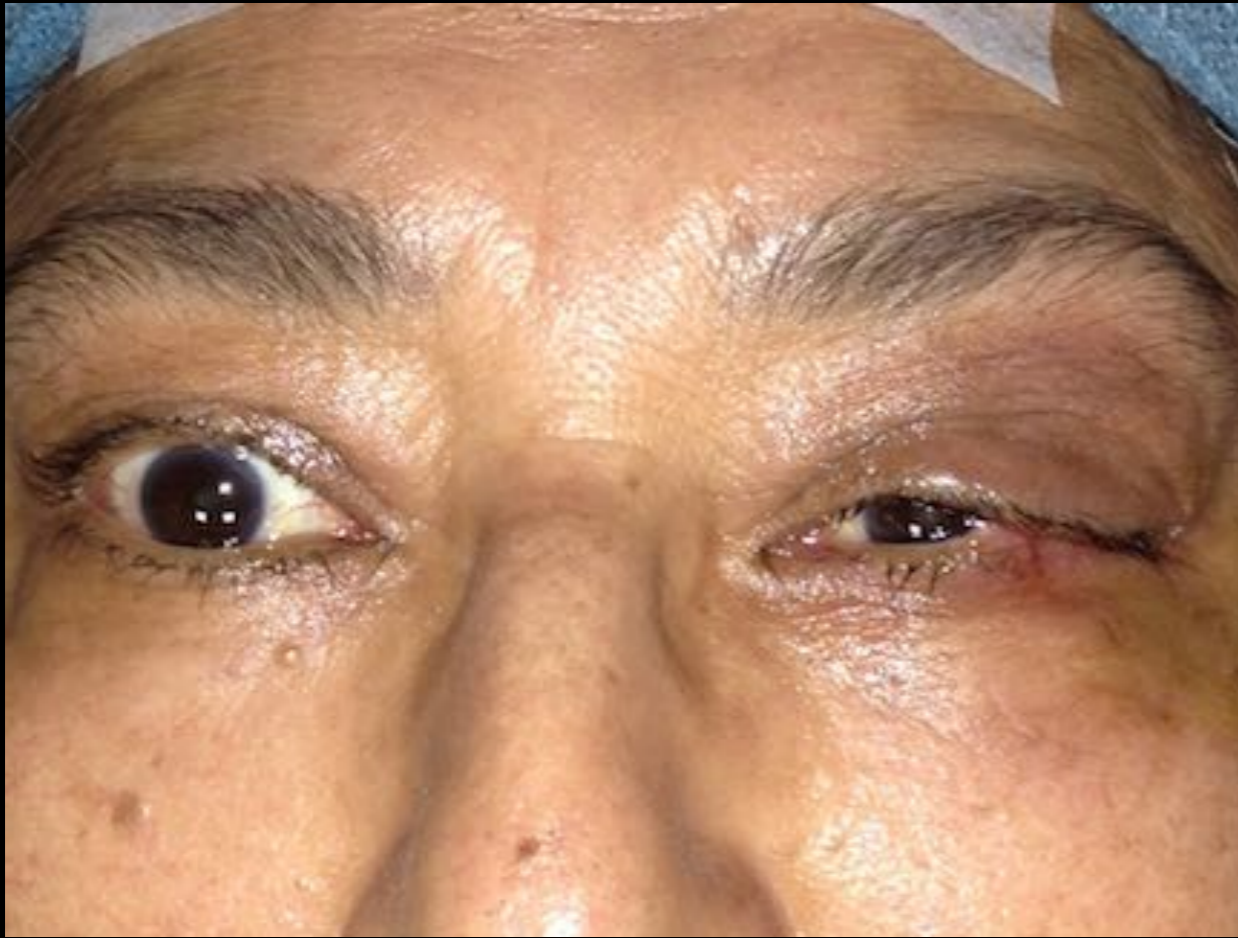
ADENOID CYSTIC CARCINOMA

WIDE EXCISION WITH FROZEN SECTION MARGIN CONTROL

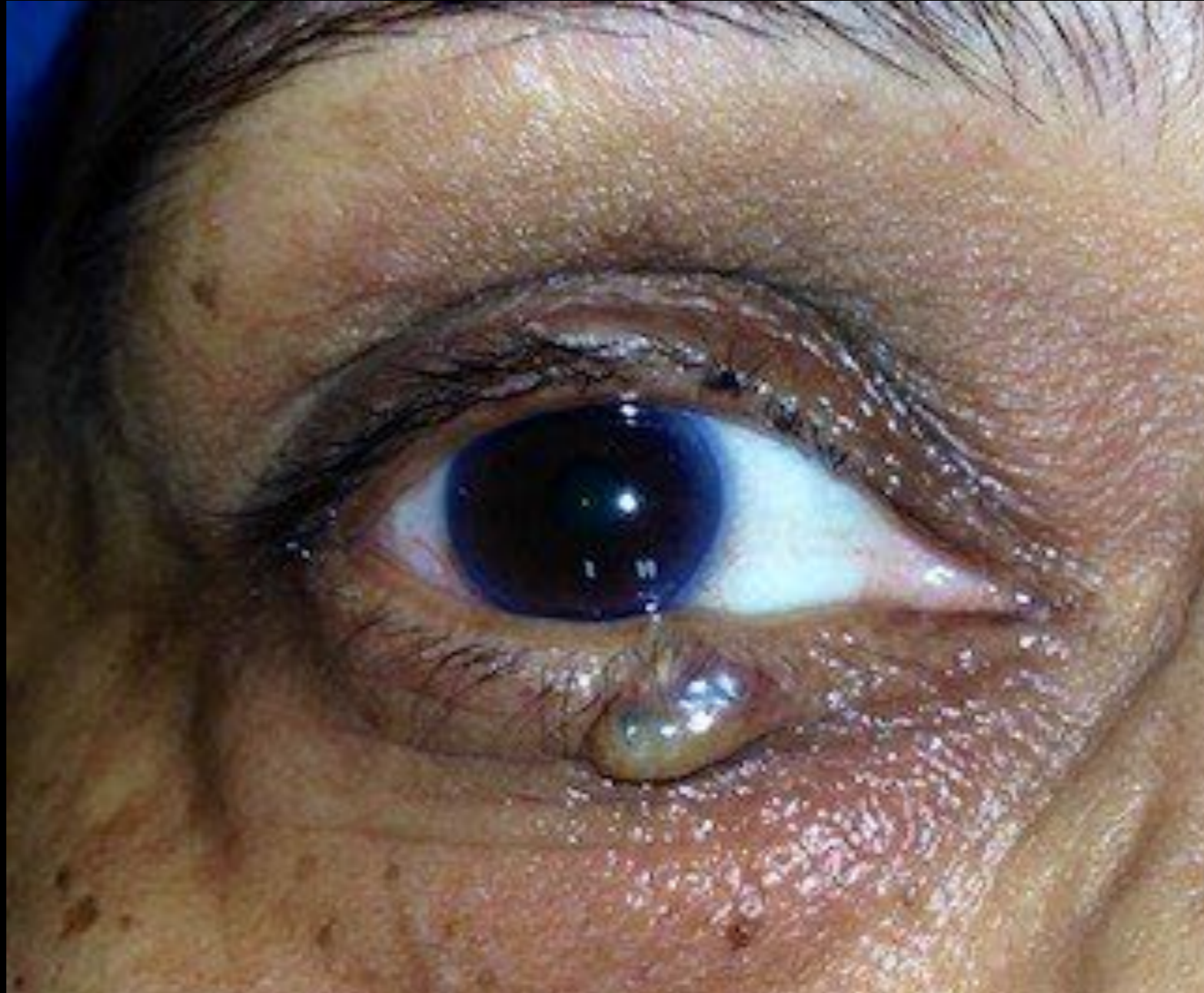

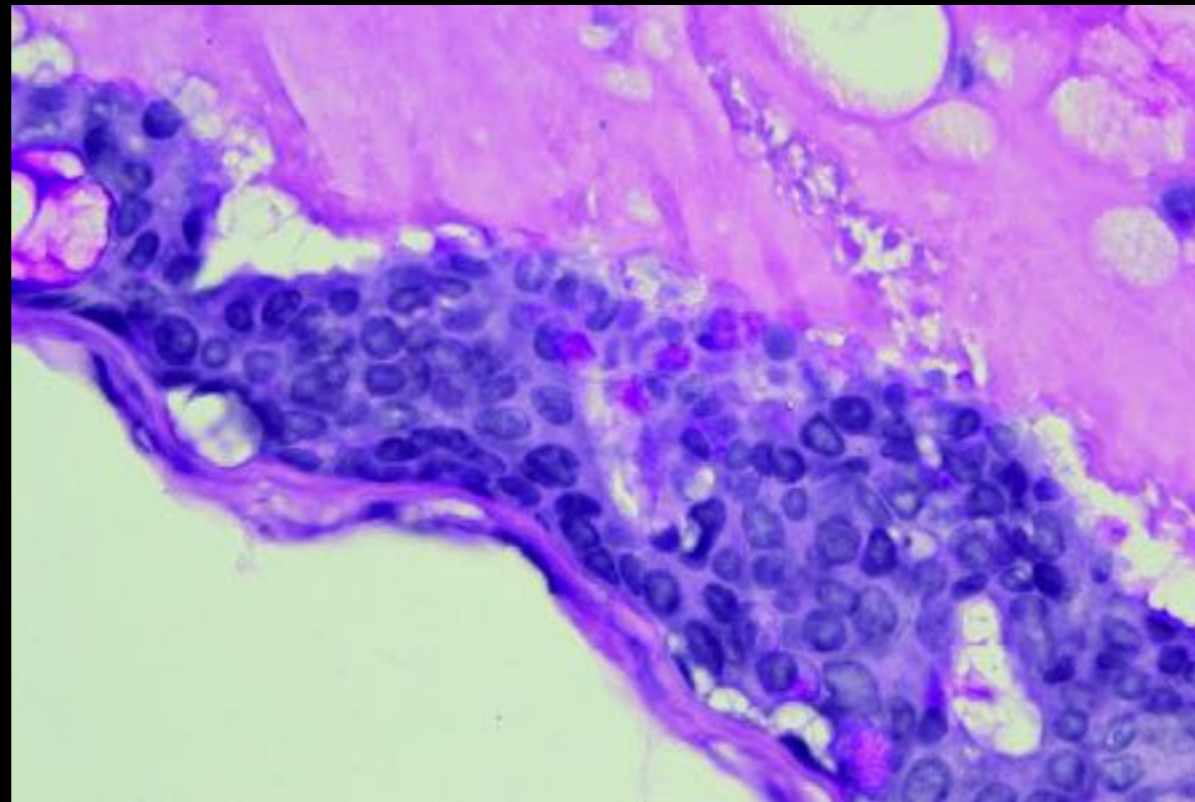
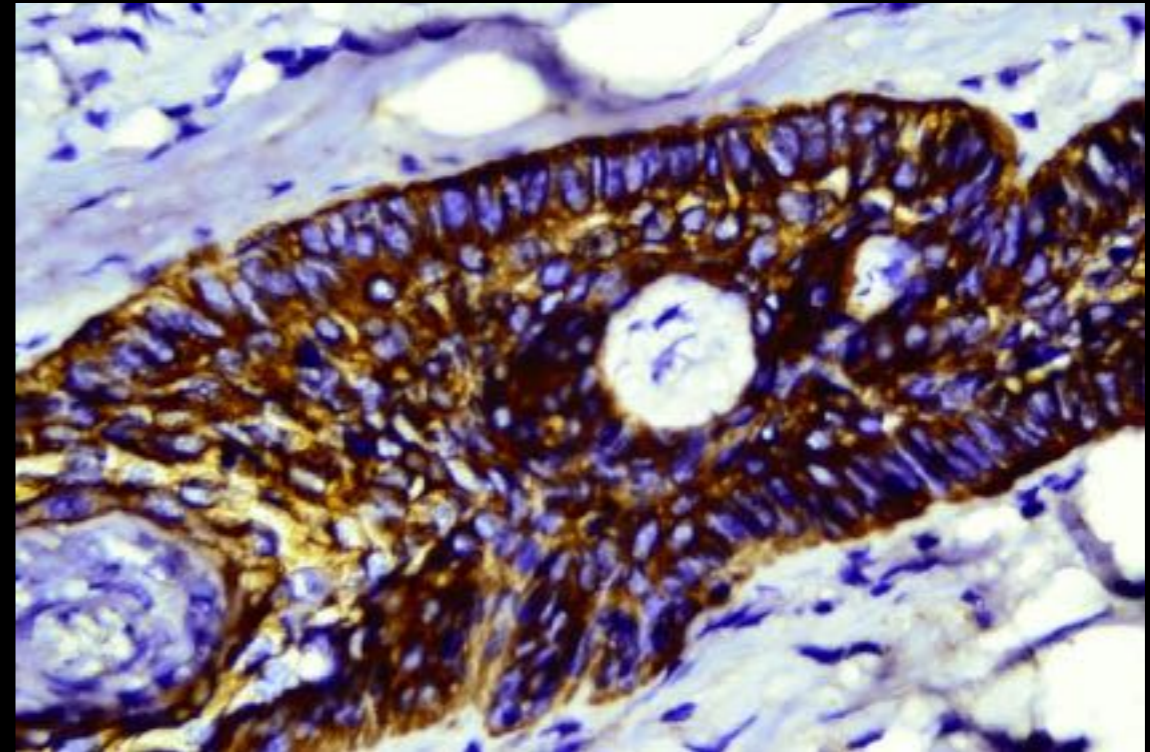
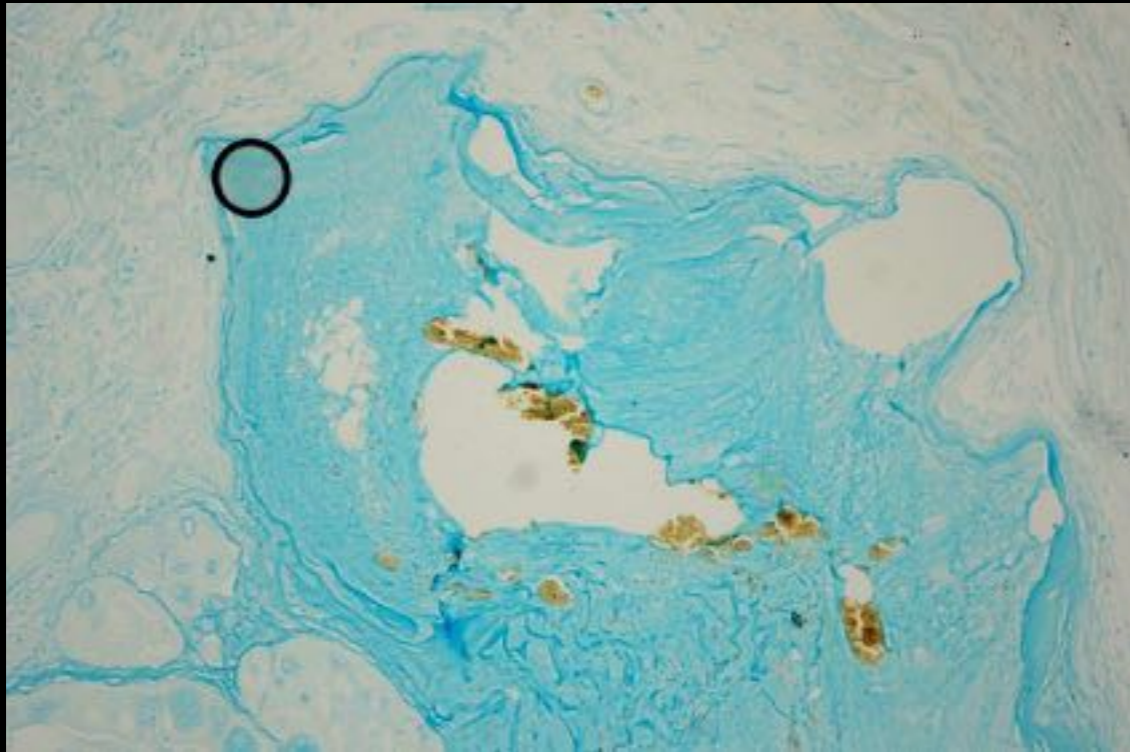
HUGHES WITH TEMPORAL ADVANCEMENT FLAP FOR RECONSTRUCTION





CASE 3



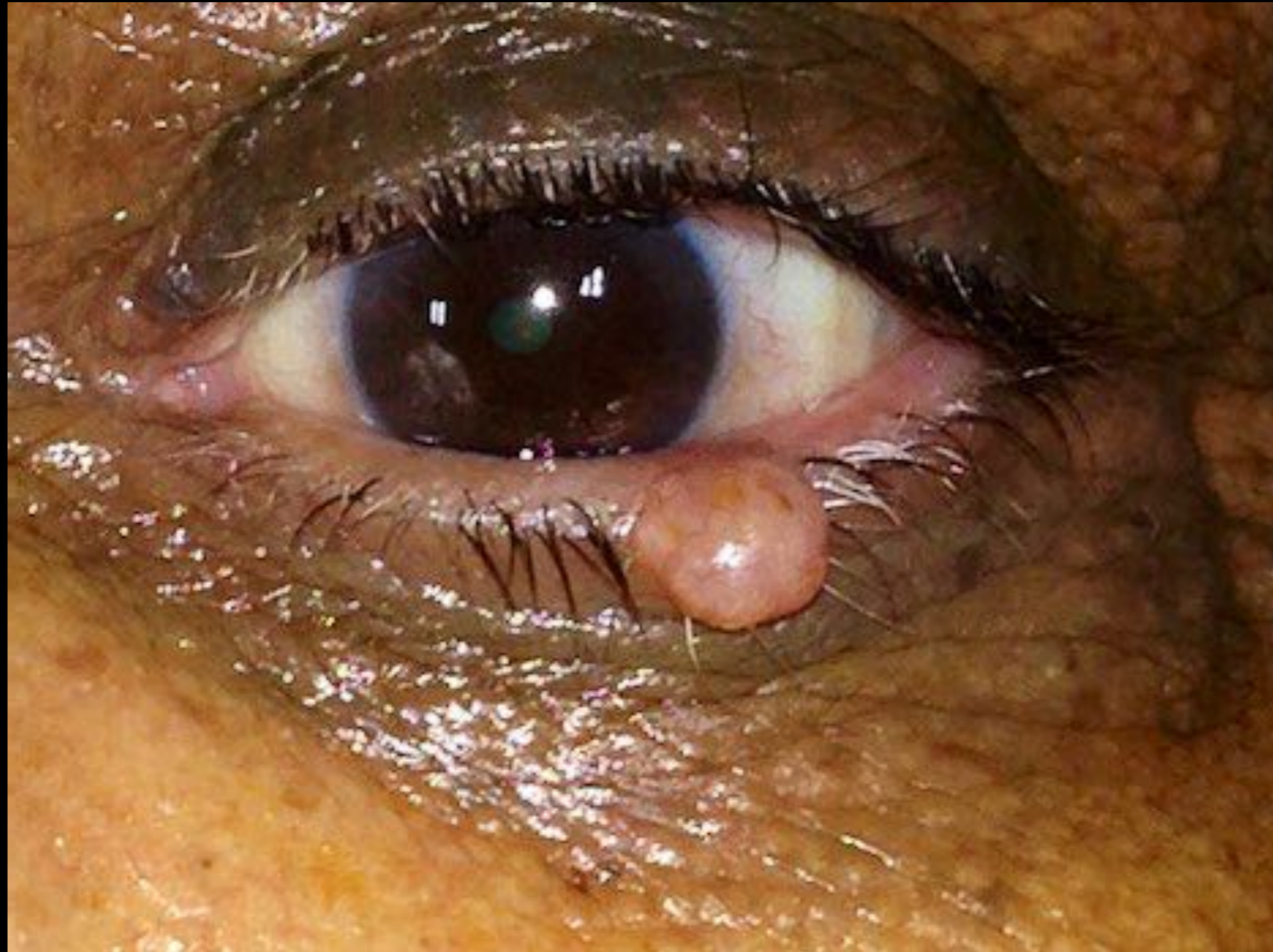

PAS positive diastase negative pattern indicates mucin

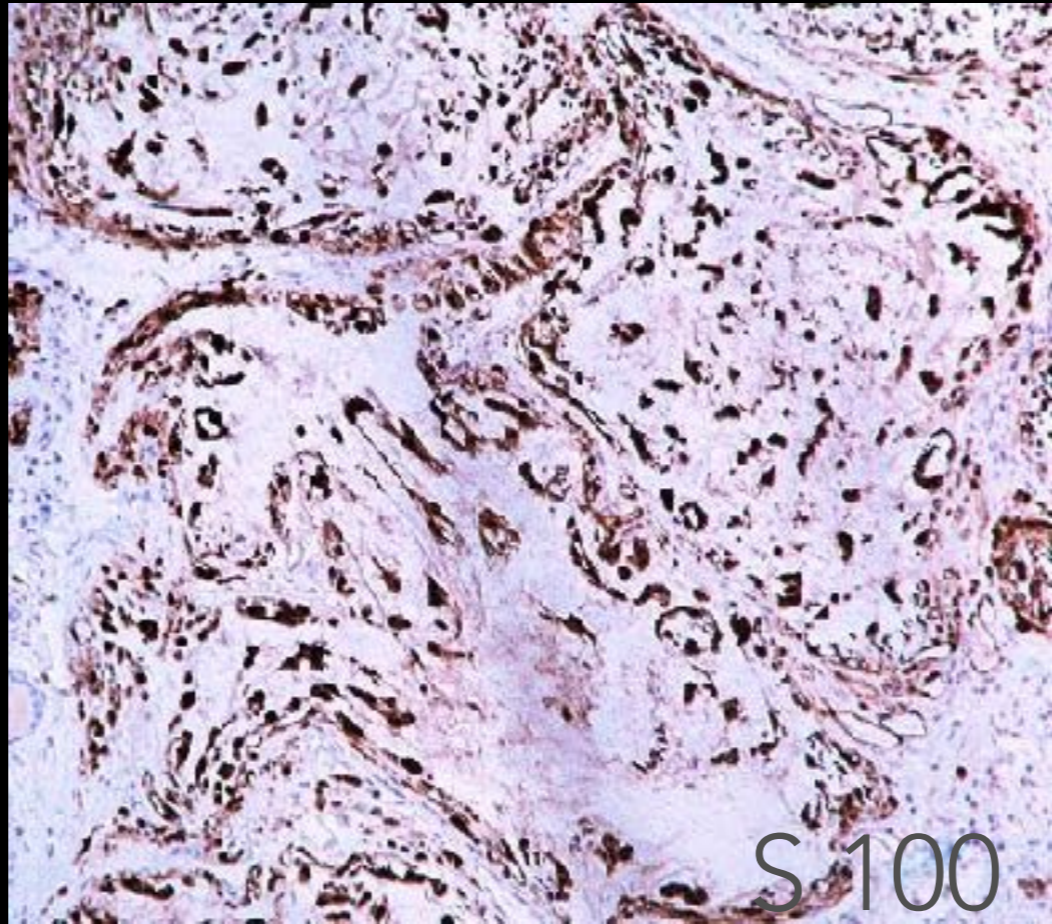
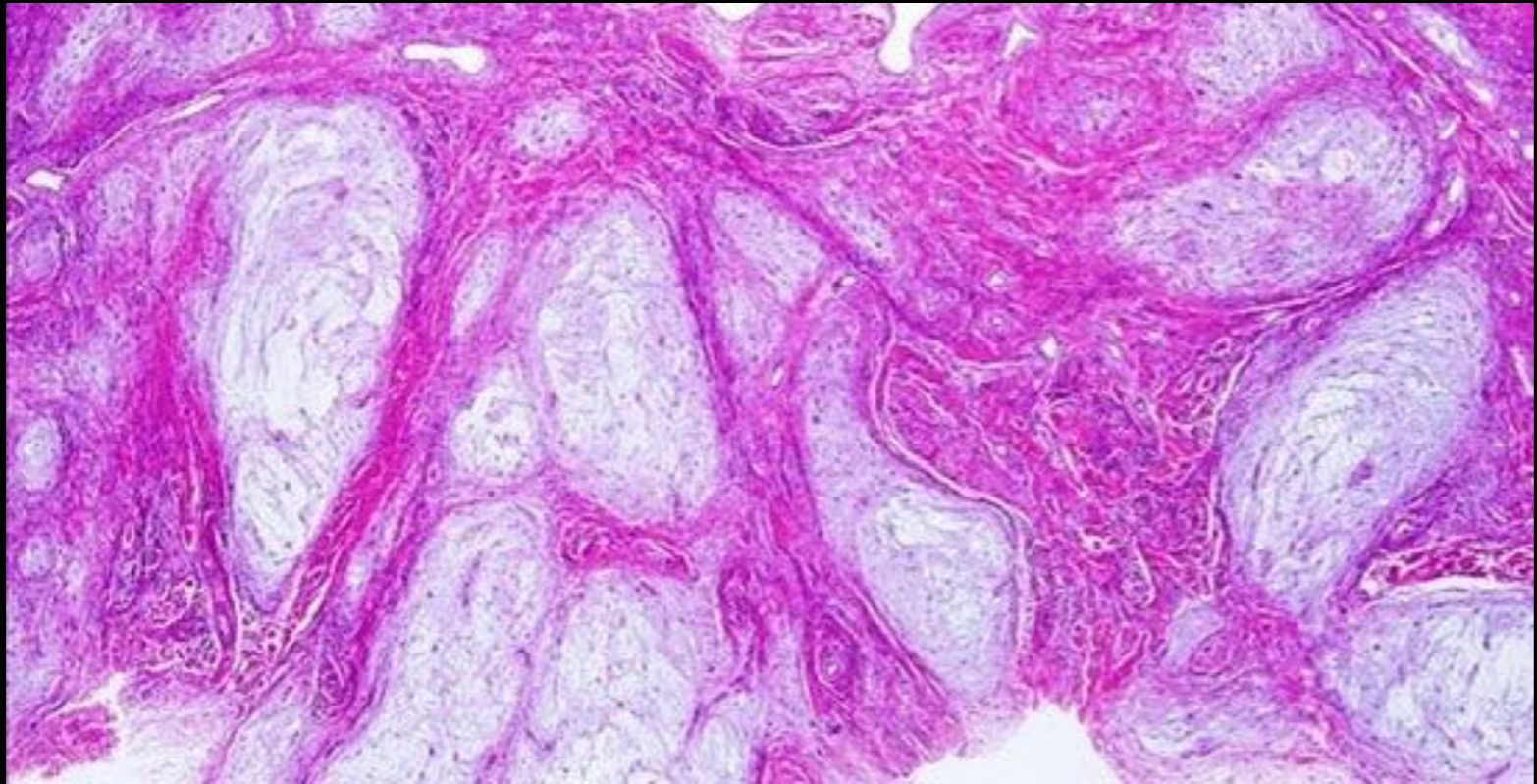
Alcian blue positivity confirms mucin

CK 7

Mucin Producing Sweat Gland Carcinoma



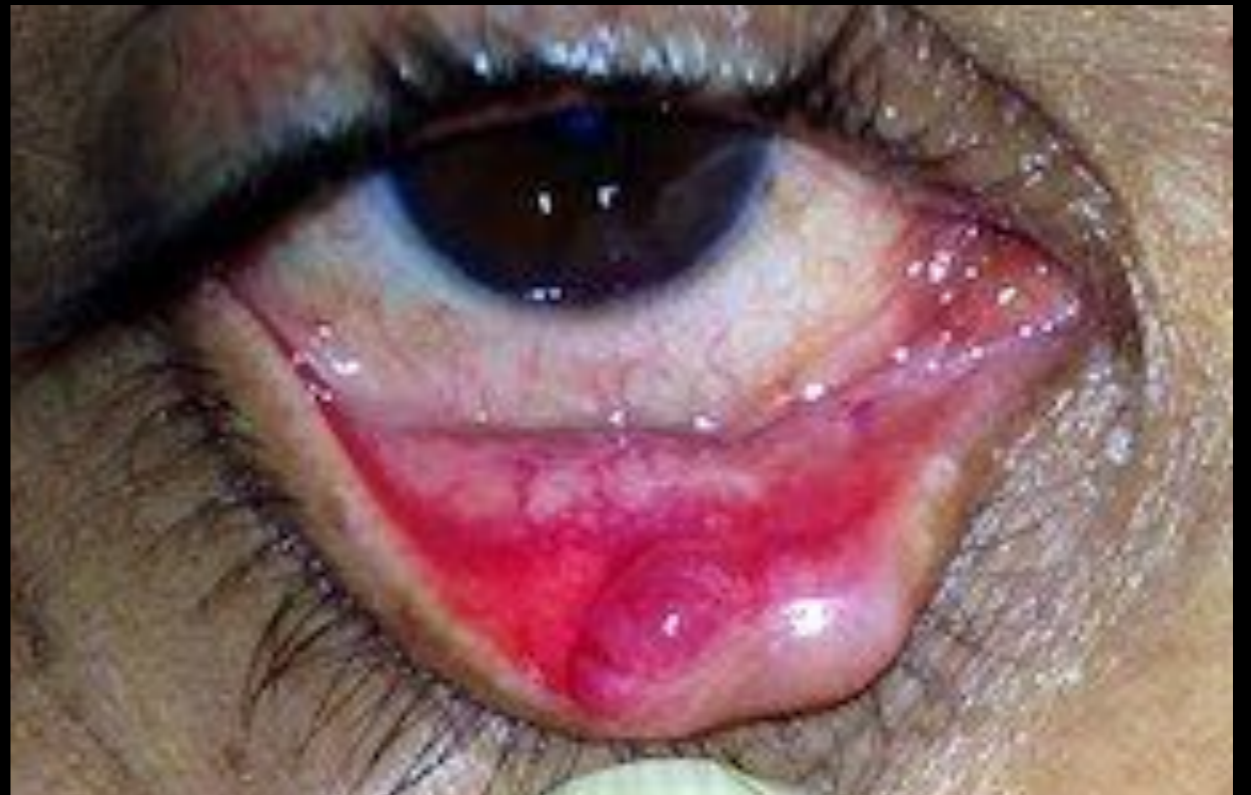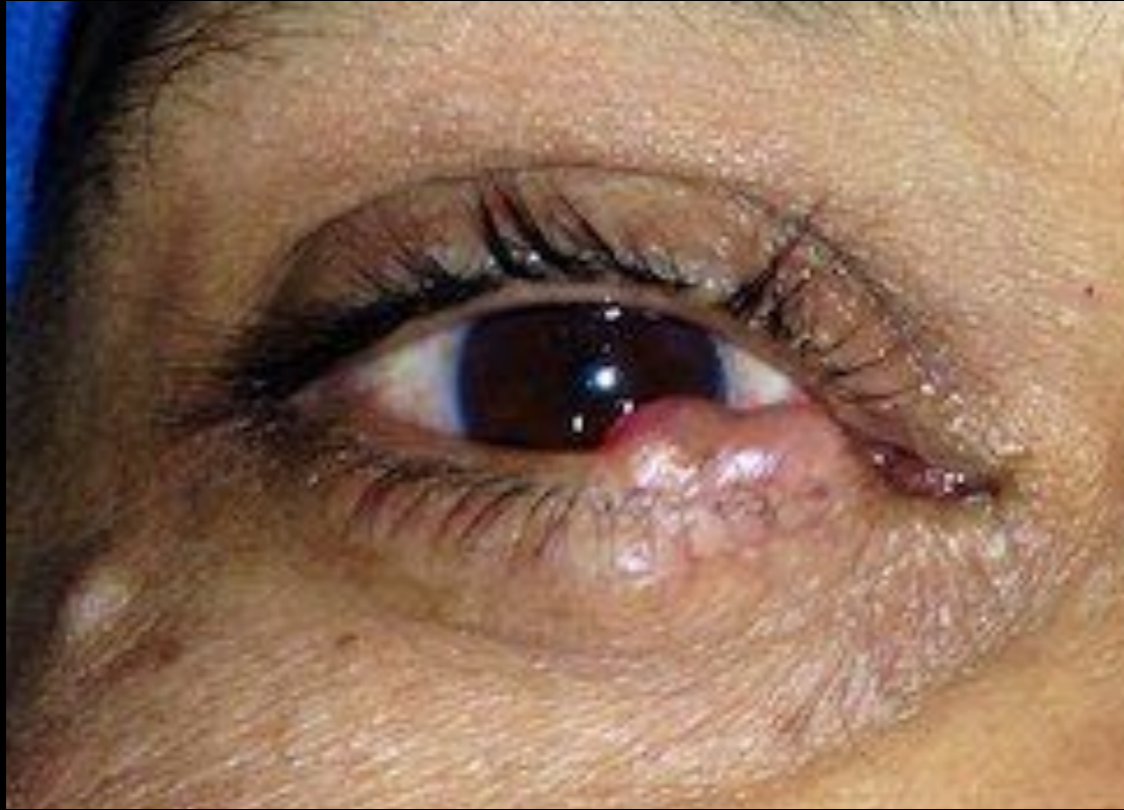69 F



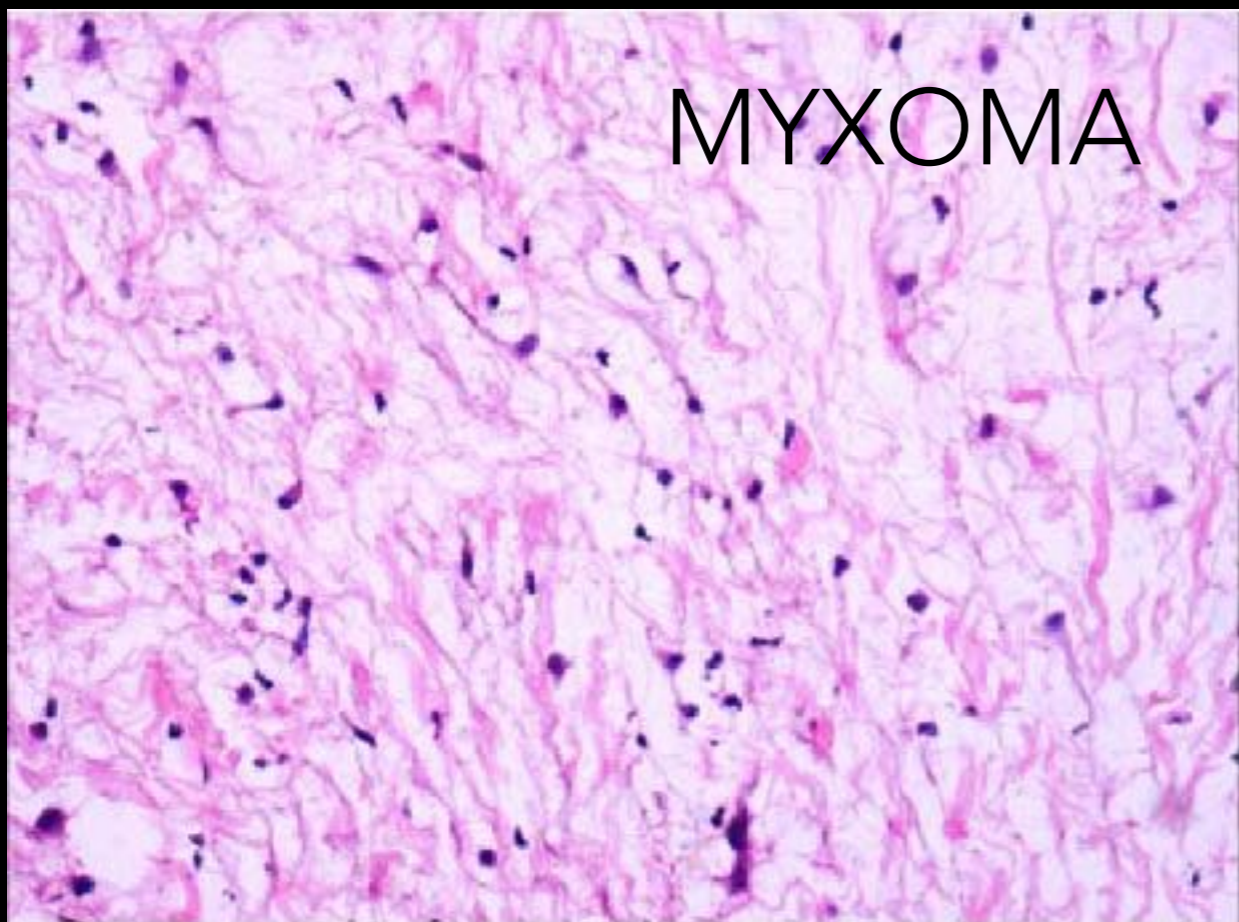
S 100

MYXOID NEUROTHEKEOMA

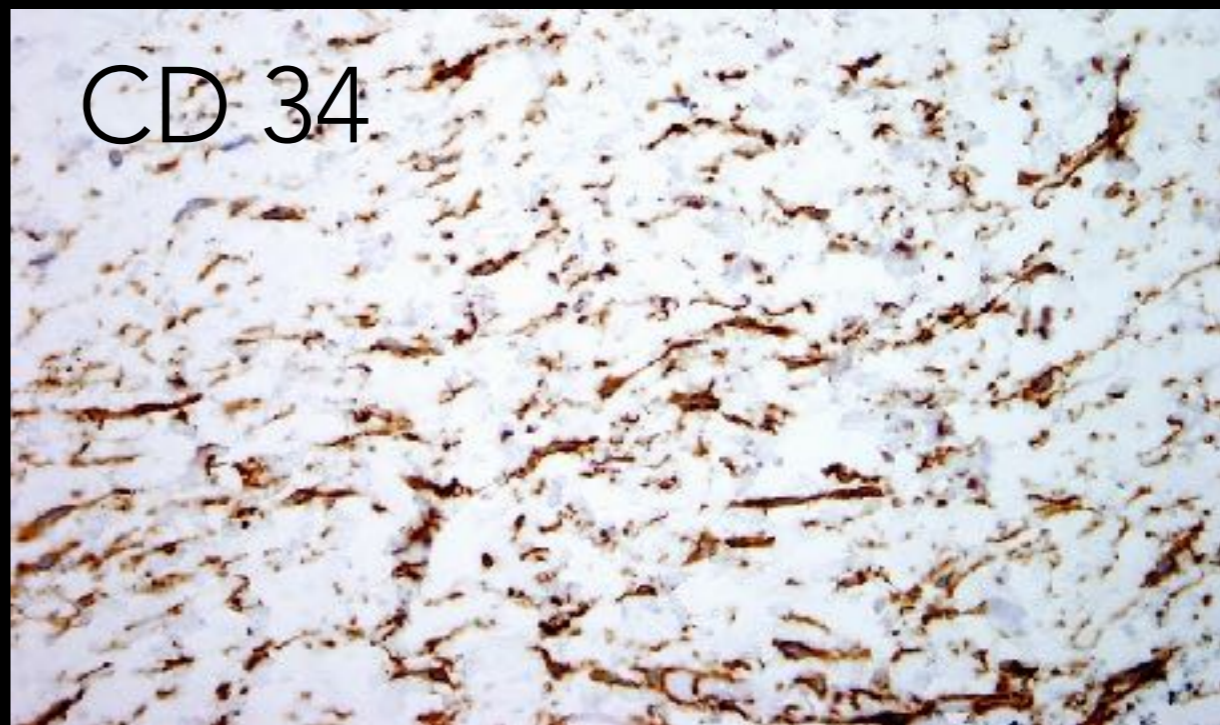
- Neurothekeoma palpebrae is the term used to describe nerve sheath myxoma



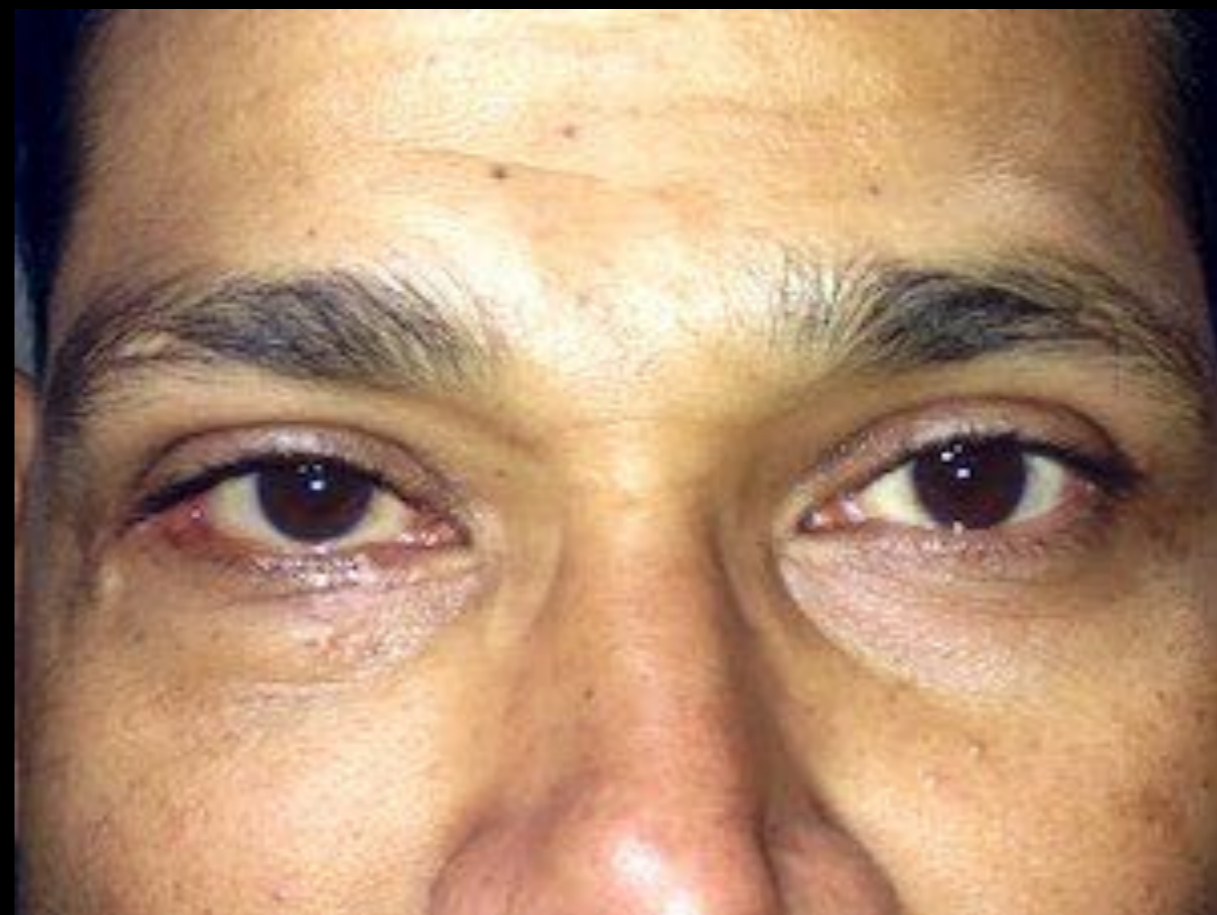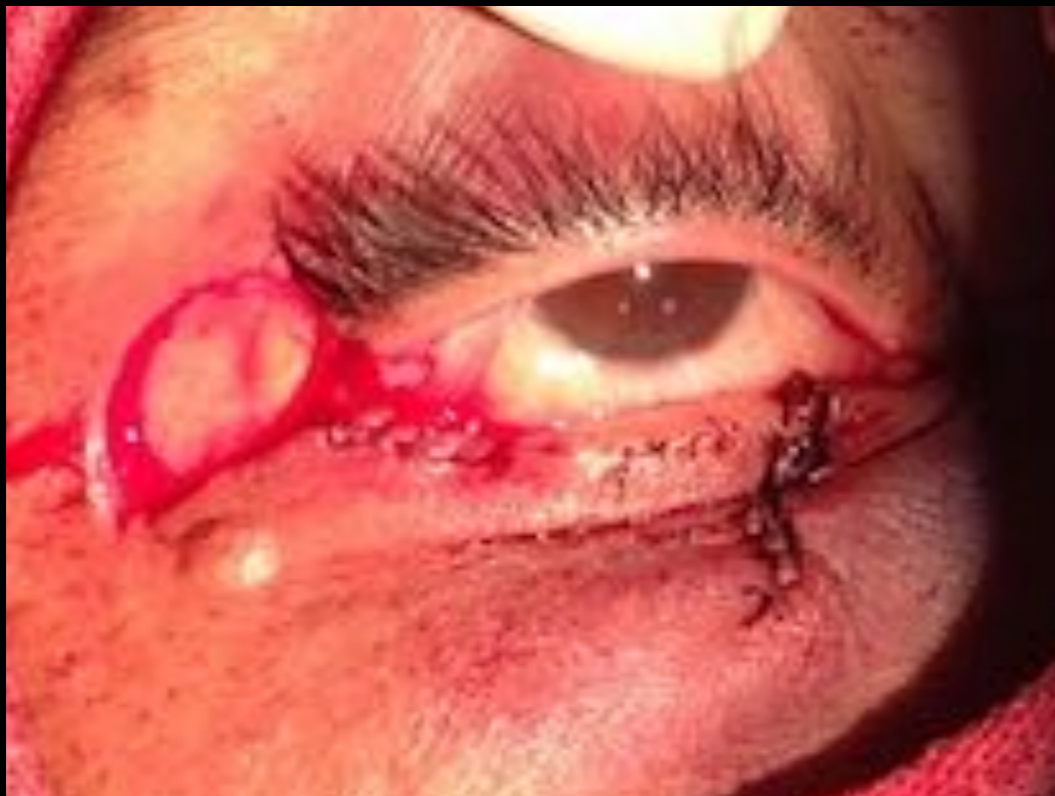MYXOMA



CD 34



RECONSTRUCTION WITH TENZEL'S FLAP



CONCLUSION

- Eyelid malignancies may masquerade as Benign lesions
- Send material to pathologist whenever a lesion looks suspicious
- Rare lesions not so rare

Thank You